



ELSEVIER



Contrast dobutamine stress myocardial perfusion echocardiography: current methodology and clinical applications

Girish Dwivedi, Roxy Senior*

Northwick Park Hospital, Harrow HA1 3UJ, UK

KEYWORDS

Dobutamine stress echocardiography;
Myocardial perfusion;
Myocardial viability;
Coronary artery disease.

Abstract Accurate evaluation of regional systolic wall thickening by echocardiography is largely dependent on adequate endocardial border resolution. Despite the recent introduction of tissue harmonic imaging, 15-20% of patients have poor endocardial border definition. Even with the use of ultrasonic contrast agents and resulting improvement in the endocardial delineation, conventional dobutamine stress echocardiography, though it has a high sensitivity for the diagnosis of coronary artery disease in patients with multivessel disease on coronary angiography, has limited ability to diagnose multivessel disease on the basis of inducible wall motion abnormalities in multivessel distributions. As in the ischemic cascade during demand stress myocardial perfusion abnormalities precede wall motion abnormalities, techniques which image myocardial perfusion as compared to wall motion are able to detect functionally significant coronary artery disease at an earlier stage and potentially at a submaximal stress. With real time myocardial perfusion imaging it is possible to simultaneously assess myocardial perfusion and function not only at rest but also during stress, which makes it a sensitive technique to detect and risk-stratify flow limiting coronary artery disease as compared to conventional wall motion imaging during stress. Furthermore, it has now become feasible to assess the changes in myocardial blood flow that occur during stress testing with the availability of softwares which makes it possible to quantitatively analyse these images, potentially improving the sensitivity and specificity of contrast echocardiography even further.

© 2006 The European Society of Cardiology. Published by Elsevier Ltd. All rights reserved.

Introduction

One of the major challenges of modern cardiology is the detection or exclusion of flow limiting coronary artery disease (CAD). Exercise electrocardiogram (ECG) is the most commonly used

technique for the diagnosis and risk stratification of patients with suspected or known CAD. However, it is well known that only 40% of patients can perform a truly diagnostic exercise test. Furthermore, the occurrence of transient ST segment depression, which is regarded as the hallmark of myocardial ischaemia, is affected by factors other than myocardial ischaemia^{1,2}. These factors, and the fact that ST-T changes occur late in the ischaemic cascade, makes exercise ECG a test of modest diagnostic accuracy for the detection of CAD. It

*Corresponding author. Roxy Senior MBBS, MD, DM, FRCP, FESC, FACC. Consultant Cardiologist and Director of Cardiac Research, Department of Cardiology, Northwick Park Hospital, Harrow HA1 3UJ, UK. Tel: +44 208 869 2547/2548; fax: +44 208 864 0075. E-mail address: roxysenior@cardiac-research.org (R. Senior).

is even less accurate in patients who have an intermediate likelihood of CAD, which comprises the bulk of the population that requires accurate risk stratification³.

Stress echocardiography was introduced in 1979 and has developed into a versatile technique for identifying patients with CAD and determining prognosis. High temporal and spatial resolution of ultrasound (2-3 mm at diagnostic frequencies) along with its relatively low cost and the rapidity with which the test can be performed at bedside are responsible for its widespread use and phenomenal growth^{4,5}.

The hallmark of myocardial ischaemia during stress echocardiography is the occurrence of reduced systolic wall thickening when myocardial oxygen demand exceeds myocardial blood supply. This precedes the occurrence of chest pain and ST-T changes. The induction of reduced regional systolic wall thickening is specific for CAD. Although exercise is a common, physiological and preferred method of stress during stress echocardiography, pharmacologic stress can be used with similar accuracy in patients incapable of adequate physical exercise.

Accurate evaluation of regional systolic wall thickening by echocardiography is largely dependent on adequate endocardial border resolution. However, approximately 20% of resting echocardiography fail to demonstrate an adequate endocardial definition, defined as ≥ 2 invisible segments at baseline, if only fundamental imaging is used⁶. Although native tissue harmonic imaging provides better endocardial delineation than standard fundamental imaging and reduces the number of patients with inadequate studies to 5-10%, ultrasonic contrast agent induced left ventricular opacification (LVO) still confers benefit over harmonic imaging⁷.

Dobutamine stress echocardiography

The induction of myocardial ischemia with conventional dobutamine stress echocardiography (DSE) is attributed to an increase in myocardial oxygen demand, with subsequent worsening of left ventricular wall motion and thickening in regions subtended by coronary arteries with significant stenoses². The increase in myocardial oxygen demand during dobutamine stress results in an increase in myocardial blood flow (MBF) similar to what is seen during vasodilator stress when dipyridamole is used⁸⁻¹². Although the presence of a physiologically relevant stenosis leads to blunting of this increase in MBF, there may still be a delay in the induction of a wall motion

abnormality. This may be the reason for modest sensitivity of conventional DSE in several clinical situations, in particular patients demonstrating single-vessel CAD on angiography¹². The weighted mean sensitivity and specificity of DSE for the detection of any stenoses greater than 50% in diameter on angiography in 40 published studies were found to be 80% and 84%, respectively^{4,5}. Although conventional DSE has a high sensitivity for the diagnosis of CAD in patients with multivessel disease on coronary angiography, its ability to diagnose multivessel disease on the basis of inducible wall motion abnormalities in multivessel distributions is limited. Indeed, several studies have shown that the majority of induced wall motion abnormalities in these patients are detected in a single-vessel distribution^{2,13}. It has been observed that approximately 10% of patients fail to achieve target heart rate during stress echocardiography, due either to limiting side effects or to chronotropic incompetence (particularly on beta-blockers), thus further reducing sensitivity of DSE⁵.

Left ventricular opacification with stress echocardiography

Patients with conditions such as obesity, chronic lung disease, on respiratory support machine or chest wall deformities offer considerable challenge. Techniques that enhance discrimination between myocardial tissue and the blood pool are particularly useful and add to the diagnostic accuracy of echocardiography. Left ventricular opacification (LVO) during contrast echocardiography enhances this discrimination and results in better endocardial delineation. This technique involves intravenous administration of perflurocarbon micro-bubbles (which have capacity to traverse pulmonary capillaries and thus appear in the left heart), and use of intermediate Mechanical Index (MI = 0.4-0.5) harmonic imaging. This technique not only enables acquisition at a high frame rate with reduced bubble destruction but also leads to production of micro-bubble harmonic signals with minimal tissue harmonic production thereby enabling maximal discrimination between the opacified blood pool and myocardium.

It has been proved in a number of stress echocardiographic studies that the use of contrast agents unequivocally improves endocardial resolution, facilitates concordant test interpretation and is of probable diagnostic benefit especially for less expert readers¹⁴⁻¹⁷.

Enhanced endocardial border definition using ultrasonic contrast agents improves the accuracy

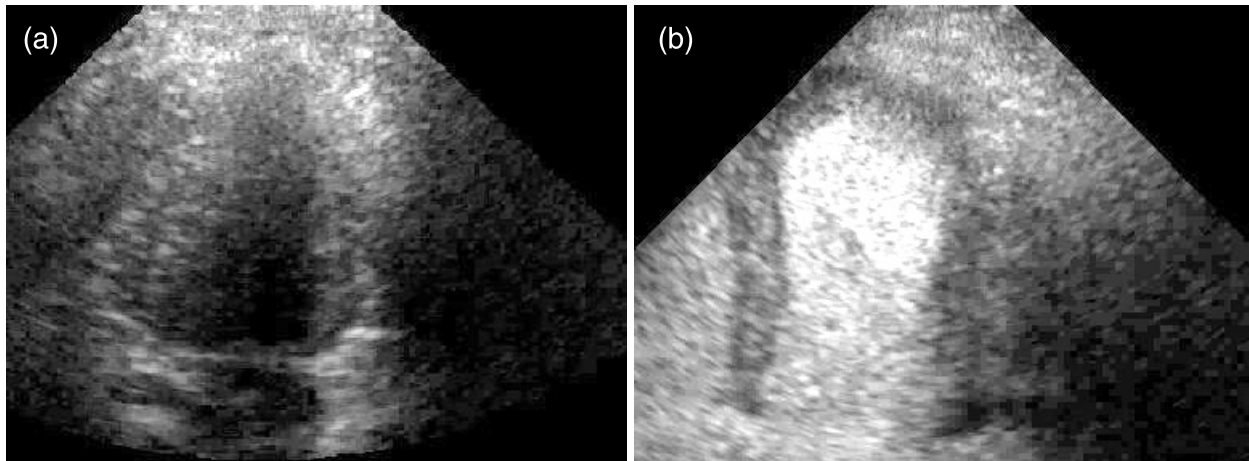


Fig. 1. (a) Apical 4-chamber view during fundamental imaging which shows poor delineation of endocardium. (b) Following a contrast injection, there is marked improvement of the endocardial visualisation of the left ventricle.

and inter-observer agreement during assessment of regional wall motion at rest¹⁷. Indeed, when compared with MRI, the number of segments visualized was improved to 99% with contrast use as compared to 86% when not used. In addition, identification of segments with abnormal wall motion improved from 82% to 100%, with maximum clinical utility of the contrast at the lateral and anterior walls. Furthermore, not only significant improvement in inter-observer agreement was observed for the individual wall segments but contrast also improved intraobserver agreement for determination of normal versus abnormal wall motion and assessment of the severity of wall motion abnormality when compared with MRI. The ability of LVO to improve scoring and inter-observer variability of regional wall motion at rest has important implications for stress echocardiography. During stress echocardiography the diagnosis of CAD requires visualization of all myocardial segments to document or exclude abnormalities definitively. During stress due to excessive chest wall movement because of hyperventilation and cardiac translational movement during tachycardia reduced endocardial border definition is exacerbated. In fact, when only fundamental imaging is used then as high as 30% of stress echocardiography may have an inadequate endocardial definition¹⁸. In addition, Hoffman et al.¹⁹ have demonstrated that suboptimal studies have less reproducibility with a poor interobserver and inter-institutional observer agreement. Tissue harmonic imaging, digital side by side analysis and standardised reporting criteria have alleviated but not completely overcome this problem²⁰. Wall motion scoring and reproducibility during stress echocardiography had improved with air filled contrast agents and fundamental imaging¹⁴.

Perfluorocarbon centred ultrasonic contrast agents demonstrate even more complete and consistent endocardial border definition with superiority even to tissue harmonic imaging, with the greatest improvement being seen in patients with poorest image quality^{15,21} (Fig. 1).

Despite these apparent advantages, it is still remains to be established whether LVO confers improved accuracy to stress echocardiography for the diagnosis of CAD. In 229 patients who underwent DSE followed by coronary angiography, Dolan et al.¹⁶ documented better endocardial border definition and interobserver variability with contrast. Moreover, they further noted that in patients with poor resting images on standard imaging, use of contrast LVO conferred comparable sensitivity, specificity and accuracy for the presence of coronary disease as compared to patients in whom standard imaging gave good resting images.

From an economic standpoint, the use of contrast agents during stress echocardiography is cost effective as well, as the cost of the contrast agent itself is more than offset by the savings incurred by reducing downstream repetitive testing, improved laboratory efficiency and a lower rate of false positive and negatives¹⁶.

Myocardial perfusion imaging

In the ischemic cascade during demand stress, myocardial perfusion abnormalities precede wall motion abnormalities²². Techniques which image myocardial perfusion as compared to wall motion are able to detect functionally significant CAD at an earlier stage of stress and potentially at a submaximal stress. Indeed, earlier studies with sestamibi during dobutamine stress have shown that in patients with CAD with demonstrable

perfusion abnormalities, the absence of concomitant wall motion abnormalities was related to a lower stress rate pressure product but not the severity of reversible ischemia as determined by quantitative sestamibi single photon emission computed tomography (SPECT) imaging²³. SPECT is a well established clinical method for the diagnosis of CAD and prediction of outcome irrespective of clinical and angiographic data²⁴⁻²⁶. However, problems such as poor image resolution, exposure to ionizing radiation, inability to perform bedside examination, and lack of widespread availability of SPECT necessitated finding an alternative method of perfusion imaging.

With real time myocardial perfusion imaging one can simultaneously assess myocardial perfusion and function not only at rest but also during stress (exercise, dobutamine or dipyridamole) and this potentially makes myocardial perfusion echocardiography a sensitive technique to detect and risk-stratify flow limiting CAD as compared to conventional wall motion imaging during stress²⁷⁻²⁹.

Furthermore, it has now become feasible to assess the changes in myocardial blood flow that occur during stress testing with the availability of softwares that make it possible to quantitatively analyse these changes. These quantitative methods may further improve the sensitivity and specificity of contrast echocardiography³⁰.

Evaluation of myocardial perfusion with contrast echocardiography has been suggested to overcome many of the potential limitations of conventional DSE and thus enhances overall and regional sensitivity, particularly at sub-maximal stress.

Physiology and methodology

Myocardial contrast echocardiography (MCE) utilises gas filled microbubbles that are inert, remain entirely within the vascular space and possess rheology similar to that of red blood cells. Following an intravenous administration, microbubbles resonate when exposed to ultrasound. The pattern and the degree of resonance are related to the acoustic power of the transmitted ultrasound field denoted as the mechanical index (MI) on the equipment. At low MI (<0.1), the microbubbles oscillate linearly, while at an MI of 0.1-0.8 the oscillation becomes non-linear. These non-linear oscillations result in generation of acoustic signals which are multiples of the incident frequency and are known as harmonics. At higher MI (>0.8) the microbubbles are destroyed producing a brief but large acoustic signal. Thus ultrasound imaging at high MI produces strong acoustic signals but images can only be

obtained during intermittent imaging. In this technique, a high-energy ultrasound is transmitted at a specified intermittent level. By incrementally increasing the interval of the ultrasound, the rate of replenishment of the microbubble over time may be assessed. Low-MI imaging results in only limited microbubble destruction, allowing continuous cardiac imaging. In this technique microbubble replenishment can be assessed by transmission of a burst of high-MI pulses which clears the microbubbles from the myocardium followed by low-MI imaging which allows observance of microbubble replenishment. This technique is particularly important in stress echocardiography as it allows simultaneous evaluation of both regional wall motion and perfusion.

Diagnosis of coronary artery disease

MCE is ideal for the measurement of microcirculatory flow. At baseline, approximately 8% of left ventricular mass is constituted by blood present in the microcirculation termed myocardial blood volume (MBV), 90% of which is comprised of blood in the capillaries. When microbubbles are administered as a constant infusion and once a steady state is achieved (approximately 1-2 minutes), the acoustic intensity measured from the myocardium after background subtraction (to eliminate native backscatter from myocardial tissue), provides a measure of MBV fraction. Because 90% of MBV fraction comprises capillary blood, a single MCE image provides an assessment of capillary density in the different myocardial regions.

Resting MBF and myocardial systolic wall thickening remains normal despite and up to 85% of luminal diameter stenosis. However, beyond 85% luminal stenosis, in absence of collateral blood flow, due to exhaustion of auto-regulation at this level of stenosis, resting MBF is reduced resulting in acute myocardial necrosis. For the detection of coronary stenosis less than 85%, hyperaemic MBF or coronary flow reserve,

$$\frac{\text{Hyperaemic MBF}}{\text{Resting MBF}}$$

needs to be measured. During maximal hyperaemia achieved by vasodilator, dobutamine or exercise stress, MBF increases by approximately 5 times the resting value, i.e., coronary flow reserve (CFR) of 5 in the normal myocardium, whereas in the myocardium subtended by >50% stenosis, CFR is much lower. MCE, by virtue of its ability to measure both resting and hyperaemic MBF, can measure CFR.

MCE has also been shown to detect coronary stenosis by visual assessment of signal intensity and microbubble velocity. During hyperaemia, in absence of significant tachycardia, myocardium subtended by normal coronary artery shows no change in microbubble signal intensity. However, in the presence of coronary stenosis, hyperaemia results in decrease in MBV proportional to the severity of stenosis and a resultant perfusion defect on MCE. The same mechanism is responsible for the occurrence of perfusion defect with radionuclide imaging. Capillary derecruitment combined with a lesser increase in RBC velocity forms the basis for stenosis detection in CAD. At rest, the RBC velocity in capillaries is 1 mm/s; therefore, following the destruction of microbubbles in the myocardium it takes approximately 5 seconds to replenish as ultrasound beam elevation is 5 mm. Normally, myocardium replenishes in 1 s during hyperaemia as there is increase in flow by 5 times. However, in regions subtended by coronary stenosis, the rate of filling is much slower depending on the severity of stenosis. In case of milder stenosis, the filling abnormality may be only confined to the sub-endocardium, which may be visualised on MCE but not seen on radionuclide imaging due to higher spatial and temporal resolution of MCE. This probably makes MCE more sensitive than radionuclide perfusion imaging in detecting reversible perfusion defects in intermediate flow-limiting stenosis³¹.

There is plenty of data demonstrating use of MCE for the detection of CAD (Table 1). Experimental studies have clearly shown that the

identification of perfusion defect enhances the ability of dobutamine echocardiography not only to detect flow-limiting CAD but also to correctly identify multi-vessel disease, which has prognostic importance^{10,22}. A number of clinical studies have been published which have established an incremental role of perfusion imaging over wall motion analysis alone in patients undergoing DSE. Xie et al.²⁸ have demonstrated in a pilot study of 27 patients that the addition of real time perfusion imaging after intravenous contrast DSE has the potential to improve detection of CAD. Porter et al.²⁷ performed MCE in 117 patients during DSE. In their study, regional myocardial contrast defects at peak stress were observed in 30 patients with >50% stenosis in at least one vessel (13 with single-vessel and 17 with multivessel disease). However, only contrast defects were observed in 17 territories subtended by >50% diameter stenosis that had normal wall motion at peak stress. Furthermore, they showed that overall agreement between quantitative angiography and myocardial contrast enhancement on a territorial basis was 83%, as compared with 72% for wall motion.

Recently, Elhendy et al.³⁴ studied 170 patients where they compared the accuracy of MCE and wall motion analysis (WMA) during submaximal and peak DSE for the diagnosis of CAD. They concluded that the majority of inducible perfusion abnormalities occurred at an intermediate phase of the stress test, without wall motion abnormalities. Indeed, they found that MCE provides better sensitivity than WMA, particularly in patients with submaximal stress and in identifying patients with multivessel CAD (Fig. 2).

Table 1
Comparison of dobutamine with dipyridamole MCE for the detection of CAD

Author	No. of patients	Sensitivity (%)	Specificity (%)
Dobutamine (n = 386)			
Elhendy et al. ³²	128	89	52
Tsutsui et al. ³³	61	92	77
Elhendy et al. ³⁴	170	91	51
Xie et al. ²⁸	27	66	100
Mean		85	70
Dipyridamole (n = 302)			
Senior et al. ³¹	55	86	88
Peltier et al. ³⁰	35	100	77
Jeetley et al. ³⁵	123	84	56
Korosoglou et al. ³⁶	89	82	84
Mean		88	76

Myocardial viability and contrast dobutamine stress myocardial perfusion imaging

The availability of an accurate, non-invasive method for distinguishing viable myocardium from myocardium that has been irreversibly damaged, following AMI or in the setting of chronic CAD, is important in clinical decision making. Such a tool would enable physicians to effectively identify patients most likely to benefit from revascularization strategies among patients with CAD and LV dysfunction. Low-dose dobutamine stress echocardiography (LDSE) is widely used to assess myocardial viability. Assessment of myocardial viability with MCE is based on persistence of capillary integrity in the viable myocardial segments. It has been suggested that presence of preserved microvasculature (capillary integrity) is

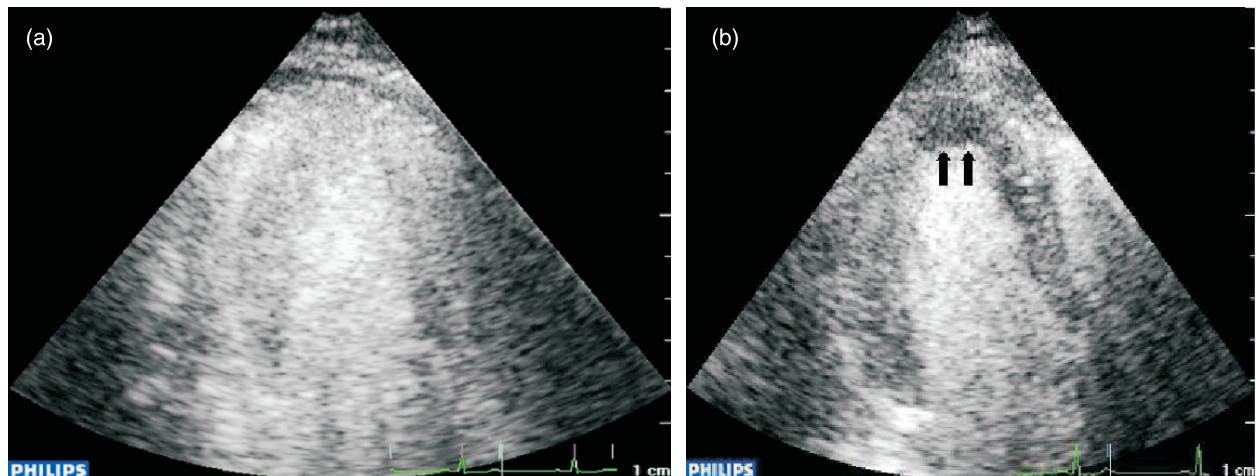


Fig. 2. Apical 3-chamber view: (a) normal myocardial perfusion observed 5 seconds after microbubble destruction; (b) subendocardial perfusion defect observed in the apex up to 6 seconds after microbubble destruction.

a more sensitive marker of recovery of function than contractile reserve on DSE, albeit at the cost of specificity^{34,37}.

Senior and Swinburn³⁸ specifically addressed the incremental value of MCE in patients undergoing LDSE for the assessment of myocardial viability following AMI. They demonstrated that the presence of contrast enhancement even in segments that lacked contractile response during dobutamine stress resulted in improvement in regional function compared to those with no contrast enhancement. Simultaneous evaluation of contractile reserve and perfusion during low-dose dobutamine stress improves detection of viable myocardium.

Risk stratification

Tsutsui et al.³⁹ retrospectively studied 788 patients and evaluated myocardial perfusion and wall motion during DSE in predicting outcome of patients with known or suspected CAD. During a median follow up of 20 months, myocardial perfusion was shown to have significant incremental value over clinical factors, resting ejection fraction, and wall motion responses in predicting events. The 3-year event free survival was 95% for patients with normal wall motion and perfusion, 82% for normal wall motion and abnormal perfusion, and 68% for abnormal wall motion and abnormal perfusion. Thus combination of perfusion and wall motion offers the best prognostic data in this group of patients.

Safety

Because of safety considerations, the possible interaction between ultrasound and tissue has

received much attention. As myocardial tissue is inherently excitable, a variety of stimuli can cause premature ventricular complexes (PVCs). It was initially thought that the combination of an inotrope like dobutamine with a strong ultrasound field will be inherently arrhythmogenic. However, although PVCs have been reported in human beings subjected to strong ultrasound fields, there have been no such reports with regard to the use of diagnostic ultrasound^{40,41}. In diagnostic ultrasound the energy level is several orders of magnitude lower and is well below the threshold for induction of PVCs. Tsutsui et al.⁴² recently reported safety and feasibility of MCE with high-dose dobutamine stress in 1486 patients. They did not find any difference in the incidence of serious ventricular arrhythmia during MCE and DSE. Thus it can be concluded that overall risk of serious adverse reactions is small if not negligible.

Limitations

It has been shown that MCE when compared with wall motion during DSE has lower specificity for CAD diagnosis³⁴. As there is attenuation of the ultrasound beam at a low mechanical index, a percentage of basal segments cannot be analyzed. When this extends into the mid segments, it becomes difficult to determine whether the lack of contrast enhancement is the result of a true increase in capillary resistance or the result of the attenuation.

Impairment of myocardial perfusion and CFR may occur in various other conditions such as hypertension, diabetes, hyperlipidaemia, and left ventricular hypertrophy adversely affecting the accuracy of MCE in the detection of flow limiting CAD. However, a regional subendocardial defect

has been shown to have a high diagnostic accuracy for the detection of CAD⁴³.

Contrast and ultrasound technology has developed at a fast pace and there is need for standardization of MCE protocols. However, with the availability of quantitative softwares, further improvement in accuracy of perfusion imaging is expected.

Conclusion

Contrast perfusion echocardiography during dobutamine stress provides valuable and incremental clinical information as compared with wall motion data alone by allowing simultaneous assessment of both function and perfusion.

References

1. Detrano R, Gianrossi R, Froelicher V. The diagnostic accuracy of the exercise electrocardiogram: a meta-analysis of 22 years of research. *Prog Cardiovasc Dis* 1989;32:173-206.
2. Marwick TH. Current status of non-invasive techniques for the diagnosis of myocardial ischemia. *Acta Clin Belg* 1992; 47:1-5.
3. Pryor DB, Harrel FEJ, Lee KL, et al. Estimating the likelihood of significant coronary artery disease. *Am J Med* 1983;75: 771-80.
4. Chaitlin MD, Armstrong WF, Aurigemma GP, et al. ACC/AHA/ASE 2003 Guideline Update for the Clinical Application of Echocardiography: summary article. A report of the American College of Cardiology/American Heart Association Task Force on Practice Guidelines (ACC/AHA/ASE Committee to Update the 1997 Guidelines for the Clinical Application of Echocardiography). *J Am Soc Echocardiogr* 2003;16:1091-110.
5. Geleijnse ML, Fioretti PM, Roelandt JR. Methodology, feasibility, safety and diagnostic accuracy of dobutamine stress echocardiography. *J Am Coll Cardiol* 1997;30:595-606.
6. Schiller NB, Shah PM, Crawford M, et al. Recommendations for quantitation of the left ventricle by two-dimensional echocardiography. American Society of Echocardiography Committee on Standards, Subcommittee on Quantitation of Two-Dimensional Echocardiograms. *J Am Soc Echocardiogr* 1989;2:358-67.
7. Al Mansour HA, Mulvagh SL, Pumper GM, et al. Usefulness of harmonic imaging for left ventricular opacification and endocardial border delineation by optison. *Am J Cardiol* 2000;85:795-9.
8. Bin JP, Le E, Jayaweera AR, et al. Direct effects of dobutamine on the coronary microcirculation: comparison with adenosine using myocardial contrast echocardiography. *J Am Soc Echocardiogr* 2003;16:871-9.
9. Lafitte S, Matsugata H, Peters B, et al. Comparative value of dobutamine and adenosine stress in the detection of coronary stenosis with myocardial contrast echocardiography. *Circulation* 2001;103:2724-30.
10. Bin JP, Pelberg RA, Wei K, et al. Dobutamine versus dipyridamole in inducing reversible perfusion defects in chronic multivessel coronary artery stenosis. *J Am Coll Cardiol* 2002;40:167-74.
11. Elhendy A, Bax JJ, Poldermans D. Dobutamine stress myocardial perfusion imaging in coronary artery disease. *J Nucl Med* 2002;43:1634-46.
12. Elhendy A, van Domburg RT, Bax JJ, et al. Accuracy of dobutamine technetium 99m sestamibi SPECT imaging for the diagnosis of single-vessel coronary artery disease: comparison with echocardiography. *Am Heart J* 2000;139:224-30.
13. Elhendy A, Geleijnse ML, van Domburg RT, et al. Gender differences in the accuracy of dobutamine stress echocardiography for the diagnosis of coronary artery disease. *Am J Cardiol* 1997;80:1414-8.
14. Porter TR, Xie F, Kricsfeld A, et al. Improved endocardial border resolution during dobutamine stress echocardiography with intravenous sonicated dextrose albumin. *J Am Coll Cardiol* 1994;23:1440-3.
15. Rainbird AJ, Mulvagh SL, Oh JK, et al. Contrast dobutamine stress echocardiography: clinical practice assessment in 300 consecutive patients. *J Am Soc Echocardiogr* 2001;14:378-85.
16. Dolan MS, Riad K, El-Shafei A, et al. Effect of intravenous contrast for left ventricular opacification and border definition on sensitivity and specificity of dobutamine stress echocardiography compared with coronary angiography in technically difficult patients. *Am Heart J* 2001;142:908-15.
17. Hundley WG, Kizilbash AM, Afridi I, et al. Effect of contrast enhancement on transthoracic echocardiographic assessment of left ventricular regional wall motion. *Am J Cardiol* 1999;84:1365-9.
18. Marwick TH, Nemec JJ, Pashkow FJ, et al. Accuracy and limitations of exercise echocardiography in a routine clinical setting. *J Am Coll Cardiol* 1992;9:74-81.
19. Hoffmann R, Lethen H, Marwick T, et al. Standardized guidelines for the interpretation of dobutamine echocardiography reduce interinstitutional variance in interpretation. *Am J Cardiol* 1998;82:1520-4.
20. Hoffmann R, Marwick TH, Poldermans D, et al. Refinements in stress echocardiographic techniques improve inter-institutional agreement in interpretation of dobutamine stress echocardiograms. *Eur Heart J* 2002;23:821-9.
21. Thanigaraj S, Nease RF Jr, Schechtman KB, et al. Use of contrast for image enhancement during stress echocardiography is cost-effective and reduces additional diagnostic testing. *Am J Cardiol* 2001;87:1430-2.
22. Leong-Poi H, Rim SJ, Le DE, et al. Perfusion versus function: the ischemic cascade in demand ischemia: implications of single-vessel versus multivessel stenosis. *Circulation* 2002; 105:987-92.
23. Elhendy A, Geleijnse ML, Roelandt JR, et al. Dobutamine-induced hypoperfusion without transient wall motion abnormalities: less severe ischemia or less severe stress? *J Am Coll Cardiol* 1996;27:323-9.
24. Klocke FJ, Baird MG, Lorell BH, et al. American College of Cardiology, American Heart Association, American Society for Nuclear Cardiology. ACC/AHA/ASNC guidelines for the clinical use of cardiac radionuclide imaging - executive summary: a report of the American College of Cardiology/American Heart Association Task Force on Practice Guidelines (ACC/AHA/ASNC Committee to Revise the 1995 Guidelines for the Clinical Use of Cardiac Radionuclide Imaging). *J Am Coll Cardiol* 2003;42:1318-33.
25. Beller GA, Zaret BL. Contributions of nuclear cardiology to diagnosis and prognosis of patients with coronary artery disease. *Circulation* 2000;101:1465-78.
26. Shaw LJ, Iskandrian AE. Prognostic value of gated myocardial perfusion SPECT. *J Nucl Cardiol* 2004;11: 171-85.

27. Porter TR, Xie F, Silver M, et al. Real-time perfusion imaging with low mechanical index pulse inversion Doppler imaging. *J Am Coll Cardiol* 2001;37:748-53.
28. Xie F, Tsutsui JM, McGrain AC, et al. Comparison of dobutamine stress echo with and without real time perfusion imaging in the detection of coronary artery disease. *Am J Cardiol* 2005;96:506-11.
29. Tsutsui JM, Xie F, McGrain AC, et al. Comparison of low-mechanical index pulse sequence schemes for detecting perfusion abnormalities during vasodilator stress echocardiography. *Am J Cardiol* 2005;95:565-70.
30. Peltier M, Vancraeynest D, Pasquet A, et al. Assessment of the physiologic significance of coronary artery disease with dipyridamole real-time myocardial contrast echocardiography. Comparison with technetium-99m sestamibi single-photon emission computed tomography and quantitative coronary angiography. *J Am Coll Cardiol* 2004;43:257-64.
31. Senior R, Lepper W, Pasquet A, et al. Myocardial perfusion assessment in patients with medium probability of coronary artery disease and no prior myocardial infarction: comparison of myocardial contrast echocardiography with ^{99m}Tc single-photon emission computed tomography. *Am Heart J* 2004;147(6):1100-5.
32. Elhendy A, Tsutsui JM, O'Leary EL, et al. Noninvasive diagnosis of coronary artery disease in patients with diabetes by dobutamine stress real-time myocardial contrast perfusion imaging. *Diabetes Care* 2005;28:662-7.
33. Tsutsui JM, Xie F, O'Leary EL, et al. Diagnostic accuracy and prognostic value of dobutamine stress myocardial contrast echocardiography in patients with suspected acute coronary syndromes. *Echocardiography* 2005;22:487-95.
34. Elhendy A, O'Leary E, Xie F, et al. Comparative accuracy of real-time myocardial contrast perfusion imaging and wall motion analysis during dobutamine stress echocardiography for the diagnosis of coronary artery disease. *J Am Coll Cardiol* 2004;44:2185-91.
35. Jeetley P, Hickman M, Kamp O, et al. Myocardial contrast echocardiography for the detection of coronary artery stenosis: a prospective multicenter study in comparison with single-photon emission computed tomography. *J Am Coll Cardiol* 2006;47:141-5.
36. Korosoglou G, Dubart AE, DaSilva Jr KG, et al. Real-time myocardial perfusion imaging for pharmacologic stress testing: added value to single photon emission computed tomography. *Am Heart J* 2006;151:131-8.
37. Meza MF, Ramee S, Collins T, et al. Knowledge of perfusion and contractile reserve improves the predictive value of recovery of regional myocardial function post revascularization: a study using the combination of myocardial contrast echocardiography and dobutamine echocardiography. *Circulation* 1997;96:3459-65.
38. Senior R, Swinburn JM: Incremental value of myocardial contrast echocardiography for the prediction of recovery of function in dobutamine nonresponsive myocardium early after acute myocardial infarction. *Am J Cardiol* 2003;91:397-402.
39. Tsutsui JM, Elhendy A, Anderson JR, et al. Prognostic value of dobutamine stress myocardial contrast perfusion echocardiography. *Circulation* 2005;112:1444-50.
40. Vancraeynest D, Hanet C, Kefer J, et al. Does contrast echocardiography cause myocardial damage in patients? *Circulation* 2003;108:624.
41. Greenstein A, Kaver I, Lechtman V, et al. Cardiac arrhythmias during non-synchronised extracorporeal shock wave lithotripsy. *J Urol* 1995;154:1321-2.
42. Tsutsui JM, Elhendy A, Xie F, et al. Safety of dobutamine stress real-time myocardial contrast echocardiography. *J Am Coll Cardiol* 2005;45:1235-42.
43. Senior R, Janardhanan R, Jeetley P, et al. Myocardial contrast echocardiography for distinguishing ischemic from nonischemic first-onset acute heart failure: insights into the mechanism of acute heart failure. *Circulation* 2005;112:1587-93.